

UC Davis

Dermatology Online Journal

Title

Adult blaschkolinear acquired inflammatory skin eruption (BLAISE) with simultaneous features of lichen striatus and blaschkitis

Permalink

<https://escholarship.org/uc/item/6394z6nc>

Journal

Dermatology Online Journal, 24(1)

Authors

Raposo, Inês
Mota, Fernando
Fernandes, Iolanda Conde
et al.

Publication Date

2018-01-01

License

CC BY-NC-ND 4.0

Peer reviewed

Adult blaschkolinear acquired inflammatory skin eruption (BLAISE) with simultaneous features of lichen striatus and blaschkitis

Inês Raposo¹, Fernando Mota¹, Iolanda Conde Fernandes¹, Áurea Canelhas², Manuela Selores^{1,3,4}

Affiliations:¹Department of Dermatology, Centro Hospitalar do Porto, Porto, Portugal, ²LAP Department of Pathology, Porto, Portugal, ³Instituto de Ciências Biomédicas Abel Salazar, University of Porto, Portugal, ⁴Dermatology Research Unit, Centro Hospitalar do Porto, Portugal

Corresponding Author: Inês Raposo, Serviço de Dermatologia, Centro Hospitalar do Porto, Edifício das Consultas Externas, Ex-CICAP, Rua D. Manuel II, s/n, 4100 Porto, Portugal, E-mail: inesraposovs@gmail.com

Abstract

Blaschkitis and lichen striatus are generally distinguished in the literature by the age of onset, lesion distribution, and histopathology. However, there is currently no clear consensus among authors about whether to consider blaschkitis and lichen striatus different clinical entities or a spectrum of the same disease. We present a case of adult BLAISE with features of both lichen striatus and blaschkitis, which seems to support the theory that these clinical entities may in fact represent a spectrum of the same pathological process.

Keywords: blaschkitis; lichen striatus; BLAISE; blaschkolinear skin eruption

Introduction

Blaschkolinearacquiredinflammatoryskin eruption (BLAISE) comprises a diversity of dermatologic entities characterized by the presence of inflammatory changes distributed along Blaschko lines [1]. There is currently no clear consensus among authors about whether to consider blaschkitis and lichen striatus different clinical entities or a spectrum of the same disease [2].

The most common clinical entities of BLAISE — blaschkitis and lichen striatus — are generally distinguished in literature by the age of onset, lesion distribution, and histopathology. Although blaschkitis

is characterized by papules and vesicles generally distributed in a spiral arrangement along multiple ipsilateral blaschko lines of the trunk of adult patients, lichen striatus lesions generally present with lichenoid papules, which tend to follow a linear pattern along blaschko lines on the extremities of pediatric patients. Whereas the former clinical entity exhibits predominantly spongiotic changes on histopathology, lichen striatus displays lichenoid changes [3].

Case Synopsis

A 21-year-old man presented with unilateral pruritic cutaneous lesions that had appeared 1 week before. There was no history of chronic disease or medication. Dermatologic examination (**Figure 1, 2**) revealed erythematous papules and vesicles distributed on the left side of the abdomen and upper left limb, grouped along these locations in a whorl and streak

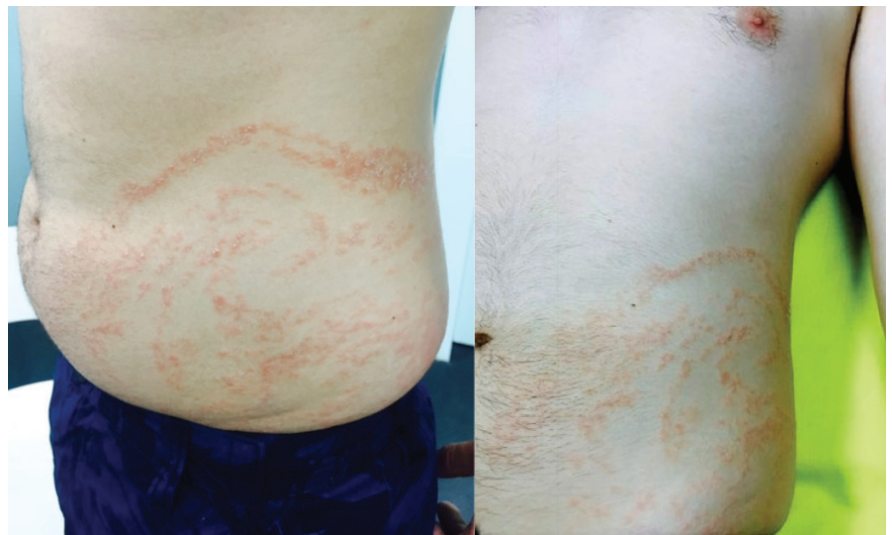

Figure 1. Clinical aspect of the lesions - erythematous papules and vesicles distributed on the left side of the abdomen grouped in a whorl configuration.

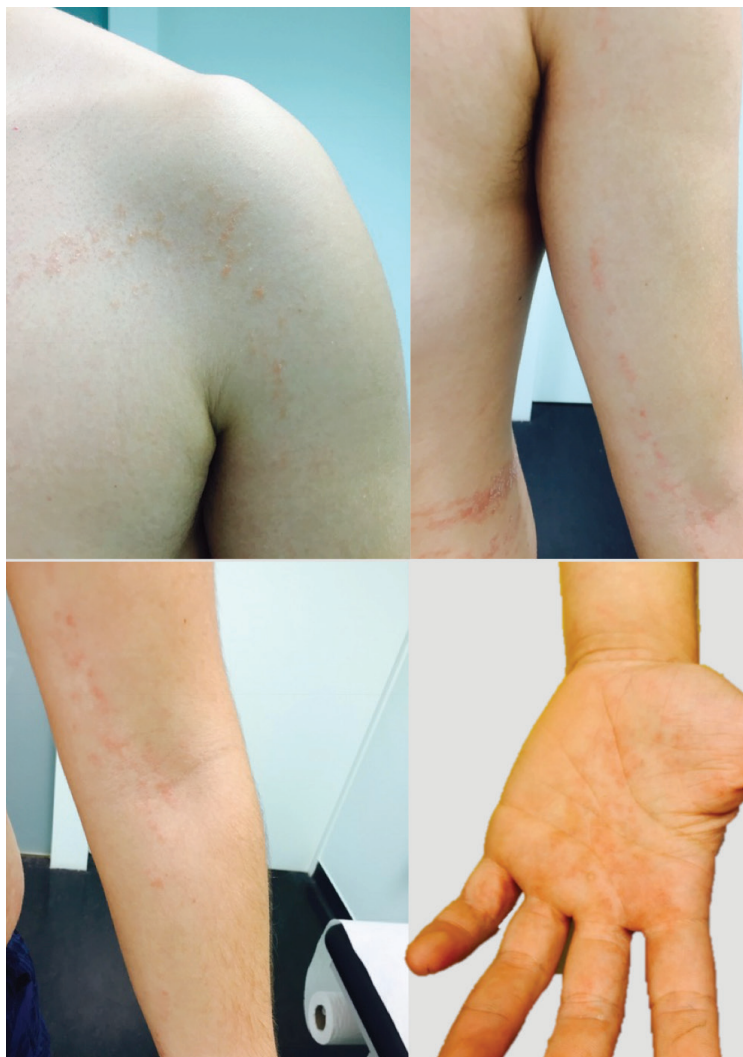

Figure 2. Clinical aspect of the lesions: erythematous papules and vesicles distributed on the upper left limb, forming a linear configuration.

configuration, respectively. A punch biopsy revealed hyperkeratosis, acanthosis, spongiosis, and lichenoid infiltrates in the dermis (**Figure 3**). The patient was treated with betamethasone cream with complete resolution of the cutaneous lesions in 3 weeks.

Discussion

In both blaschkitis and lichen striatus an external acquired stimulus (e.g. infection, trauma) or autoimmune phenomenon (e.g. triggered by somatic mutations in keratinocytes) may lead to T-cell mediated inflammatory reaction directed against human keratinocyte mosaics present along Blaschko lines [4, 5]. Although the same theoretical triggers are reported, the reason why the cutaneous reaction pattern has such differing clinical and histological characteristics in pediatric and adult patients remains unsolved [1, 6].

Conclusion

We describe a man with a clinical presentation and histopathology with overlap features consistent with both blaschkitis and lichen striatus. Our case seems to support the opinion of some authors who suggest that these clinical entities may in fact represent a spectrum of the same pathological process.

References

1. Muller CS, Schmaltz R, Vogt T, Pfohler C. Lichen striatus and blaschkitis: reappraisal of the concept of blaschkolinear dermatoses. *Br J Dermatol*. 2011;164(2):257-62. [PMID: 20849467].
2. Ro YS, Shin YI. A case of lichen striatus following Blaschko lines. *Cutis*. 2001;67(1):31-2, 4. [PMID: 11204601].
3. Keegan BR, Kamino H, Fangman W, Shin HT, Orlow SJ, Schaffer JV. "Pediatric blaschkitis": expanding the spectrum of childhood acquired Blaschko-linear dermatoses. *Pediatric dermatology*. 2007;24(6):621-7. [PMID: 18035983].
4. Patrizi A, Neri I, Fiorentini C, Chiericato C, Bonci A. Simultaneous occurrence of lichen striatus in siblings. *Pediatric dermatology*. 1997;14(4):293-5. [PMID: 9263312].
5. Hafner C, Landthaler M, Vogt T. Lichen striatus (blaschkitis) following varicella infection. *J Eur Acad Dermatol Venereol*. 2006;20(10):1345-7. [PMID: 17062066].
6. Hofer T. Lichen striatus in adults or 'adult blaschkitis'?. There is no need for a new naming. *Dermatology (Basel, Switzerland)*. 2003;207(1):89-92. [PMID: 12835564].

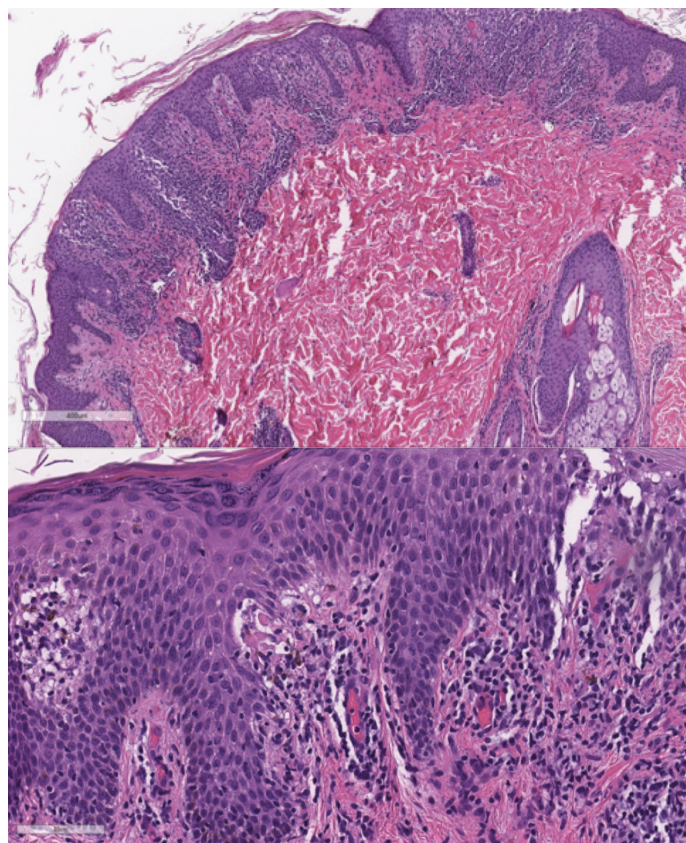


Figure 3. A) Hyperkeratosis, acanthosis, spongiosis, and lichenoid infiltrates in the dermis. H&E, 10%. B) Spongiosis, lichenoid infiltrates in the dermis, and apoptotic keratinocytes. H&E, 40%.